

# T-CAT and cross-linking

## A new option for keratoconus?

Consultant ophthalmologist **Chad Rostron** explains a new treatment for keratoconus with implications for optometrist co-management

**C**orneal collagen cross-linking with riboflavin and UV light has been shown to be effective in preventing progression of keratoconus, and many ophthalmologists are now recommending this treatment to stabilise the cornea where there has been documented evidence of recent progression of the disease. However, cross-linking may have an additional new role as a method of strengthening the cornea, for the purpose of offsetting simultaneous weakening induced by excimer laser surface ablation. Historically, keratoconus was regarded as an absolute contra-indication to excimer laser treatment because of the likelihood of further mechanical destabilisation of the cornea, and exacerbation of the ectasia. It is well recognised that ectasia may arise as a complication of laser refractive surgery, and this is more common following Lasik rather than surface laser ablation, due to the deeper and larger area of stromal lamellar disruption created by the combination of laser and Lasik flap. With surface ablation (PRK, Lasek, Epi-Lasik) not only is the laser ablation made in a more superficial part of the stroma, but the stromal disruption is confined to a smaller area of the cornea since Lasik flaps are always designed to be larger than the proposed treatment area, so it is perhaps not surprising that post-laser ectasia is less common following PRK than Lasik.

### T-CAT

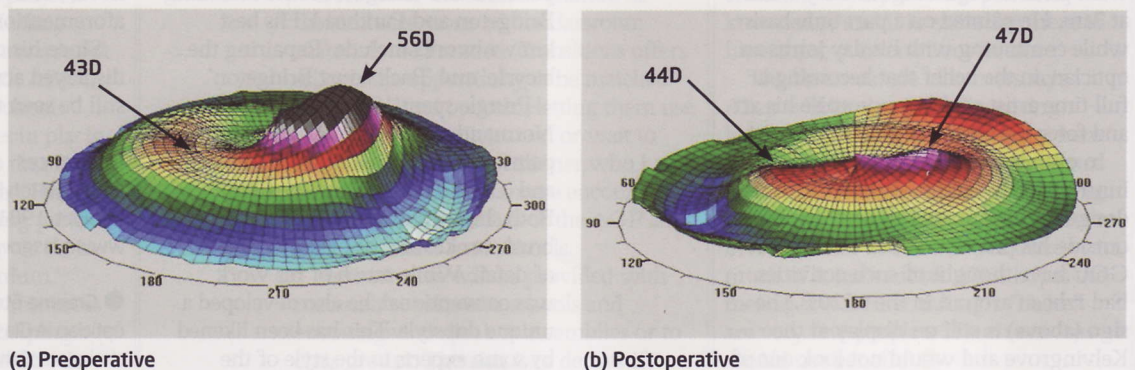
T-CAT (Topography-guided Custom Ablation Treatment) is a patented

software which allows the Wavelight laser platform to deliver a treatment profile that is based exclusively on the patient's topography data. While the conventional refractive components of sphere and cylinder may be simultaneously incorporated into the treatment profile, in the treatment of keratoconus, tissue sparing is a prime consideration, so a correction of the overall refractive defect is generally unrealistic. However, by targeting the corneal asymmetry and irregular astigmatism commonly seen in keratoconus, the T-CAT treatment can potentially restore the central optical zone to a shape that is compatible with good spectacle-corrected vision (Figure 1). So the question is: if the T-CAT treatment is combined with cross-linking, is the small amount of weakening induced by the laser sufficiently offset by the strengthening effect achieved by the cross-linking? Research studies are underway, but it will be years before we have any sort of clear answer to this question. Since keratoconus is very variable in its severity and course, the assessment of such treatments is fraught with difficulty. Even the acceptance of simple cross-linking alone as a treatment has been slow, as all the earlier clinical studies were of an observational nature, and it is only latterly that randomised controlled trials have confirmed the benefit of this therapy.

So who should be given these treatments, and in what order? To inform our discussion, let us take a look at simple cross-linking alone in a little more detail.

### Standard cross-linking

A standard cross-linking procedure involves the removal of the central area of corneal epithelium, to allow penetration of the riboflavin (vitamin B2) into the corneal stroma. The riboflavin drops are made up in a high molecular weight dextran solution, such that the drops are osmotically equivalent to the corneal stroma, in order to avoid causing corneal oedema. Drops are applied regularly for about 20 minutes to achieve uniform equilibration of the riboflavin throughout the stroma, and good penetration of riboflavin into the anterior chamber. The UV illumination is at 365nm, a frequency chosen to coincide with an absorption peak of the riboflavin. UV irradiance is 3mW/cm<sup>2</sup>, and is applied for 30 minutes. The riboflavin has a dual action in the treatment: firstly the excited riboflavin molecules are what produce the chemical reaction that creates the strengthening of the collagen structure, and secondly the riboflavin acts as a shield, absorbing the UV and preventing it from entering into the eye and potentially damaging intraocular structures. In the central stromal area, corneal keratocytes are killed by the cross-linking process to a depth of 300µ by this standard treatment, and it is for this reason that it is recommended that the initial corneal thickness is at least 400µ in order that the cellular depleting effects of the treatment do not reach so far into the cornea as to reach and damage the endothelial cells. Indeed because the UV is so strongly absorbed by the riboflavin, little UV gets as far as the inner cornea, with the majority of the cross-linking



**Figure 1** Change in corneal contour after T-CAT and cross-linking

(a) Preoperative

(b) Postoperative



and strengthening effect being in the most superficial corneal layers.

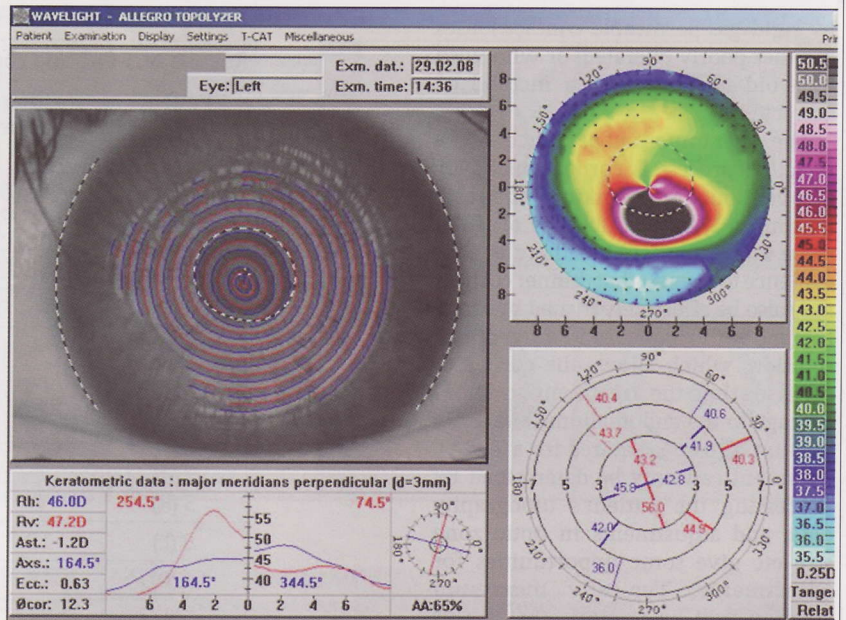
At the completion of the cross-linking, the cornea has a central epithelial defect, and this typically takes several days to heal. The eye will be painful, watery, and photophobic, and strong systemic analgesia is required. A bandage soft contact lens is usually worn until epithelial cover is re-established, and topical steroid/antibiotic drops are tapered over several weeks to control the postoperative wound healing process. As with surface laser treatments, an uncontrolled wound healing response can lead to surface haze or scarring, with potential diminution of the best corrected acuity.

**Combined T-CAT and cross-linking**

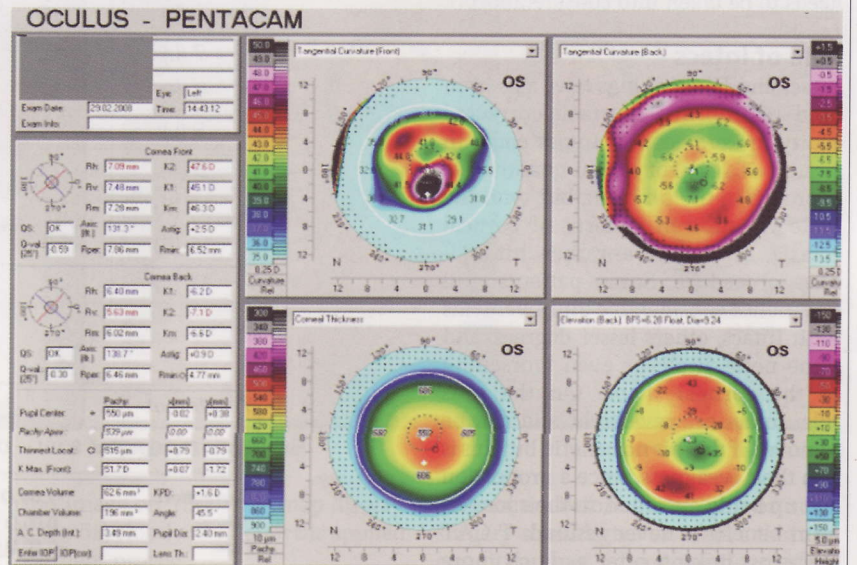
It might seem a sensible approach to stabilise keratoconus with cross-linking first, before attempting any laser treatment. However, such a sequential treatment has two disadvantages: firstly, if the laser treatment is applied to the stromal surface that has been previously cross-linked, one is in fact ablating the very tissue that has been most effectively strengthened by the cross-linking. Secondly, by doing a repeated epithelial removal, and incurring a second surface wound healing response, the eye may be more likely to react with an excessive response, causing sub-epithelial scarring. Thus a combined treatment, with the T-CAT first, followed with an immediate cross-linking, would seem to be the favoured strategy.

**Case selection**

So which patients should be offered simple cross-linking, and which combined T-CAT and cross-linking treatment? The research studies on simple cross-linking naturally concentrated on treating cases where there was documented evidence of disease progression, in order to more clearly define the benefits of the treatment. But the progression of keratoconus is essentially an unpredictable affair, and past performance is not necessarily a predictor of future change. So if one is to wait until one has hard data demonstrating deterioration of the corneal shape before applying treatment, then all one has done is allowed the vision to deteriorate (without necessarily being able to offer any remedy for this), and then to offer a prophylactic treatment to assumedly prevent further progression which might not ever occur anyway! So, from a pragmatic perspective, the application of simple cross-linking needs to be offered on the basis of assumed risk



**Figure 2**  
 Corneal data from the Topolyzer (top) and the Pentacam



of future progression. Unfortunately we do not have any tools to quantify such risk, and the only parameter that has been shown to predict severity of keratoconus is age of onset, with those starting the disease earliest developing the worst outcomes. Virtually all the published data on cross-linking has been on adults, and yet it is the youngest teenagers who could be considered to be those in most urgent need of cross-linking, and we certainly need further studies to look more critically at this aspect.

With increasing age, everyone's cornea becomes progressively more rigid, due to natural age-related cross-linking, and it is probably for this reason that the likelihood of progression of keratoconus diminishes with age, and is rarely seen in the 40+ age group. So simple cross-linking can be offered to all patients with keratoconus under 40,

with those in their teens and twenties being particularly motivated to progress to treatment.

Combined T-CAT and cross-linking is a more invasive procedure than simple cross-linking, with the trade off being that a greater reduction of corneal distortion can be anticipated with the T-CAT. Long-term follow-up after simple cross-linking has shown some reduction in steepness and improvement of symmetry in a large proportion of patients, but the reductions of steepness are typically of the order of only 1-2 D, which in a cornea with a maximum K in the 50s is overall not a big change. Much more substantial reductions in steepness and asymmetry can be anticipated after T-CAT, so the target population for this procedure are those with a degree of asymmetry that is impacting on the quality of their best spectacle-corrected visual acuity, and for whom correction







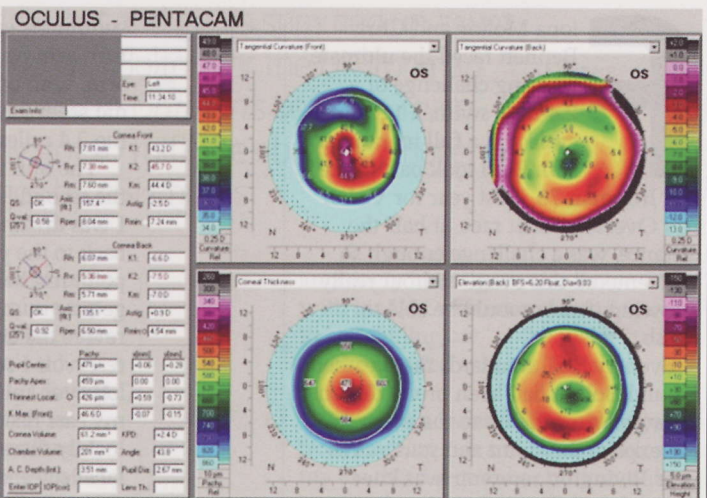
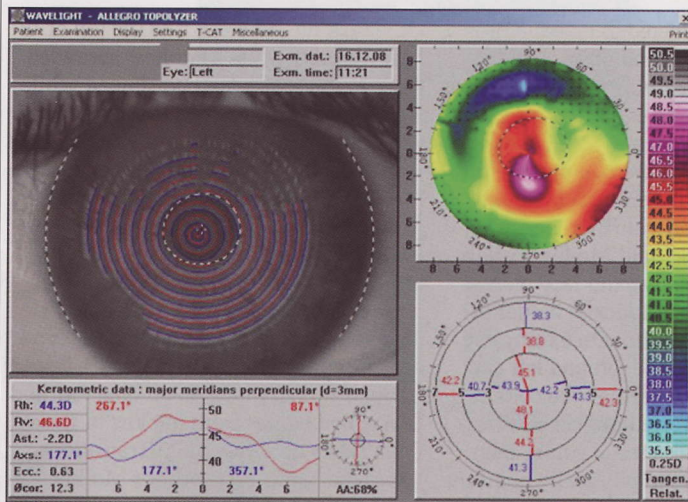
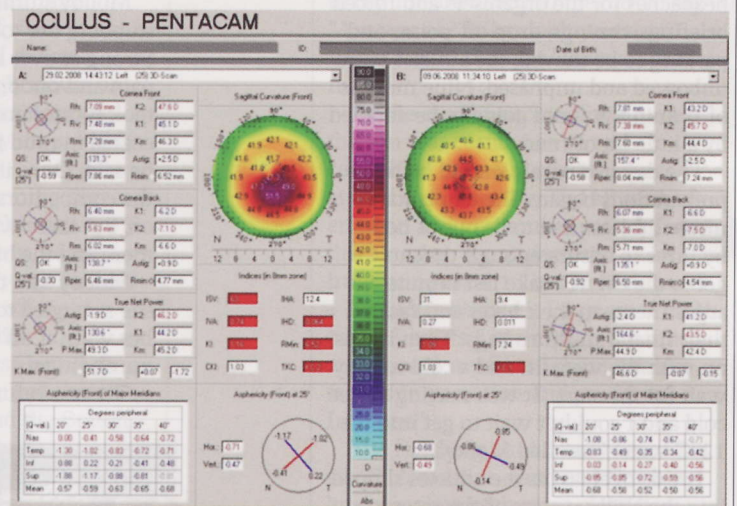
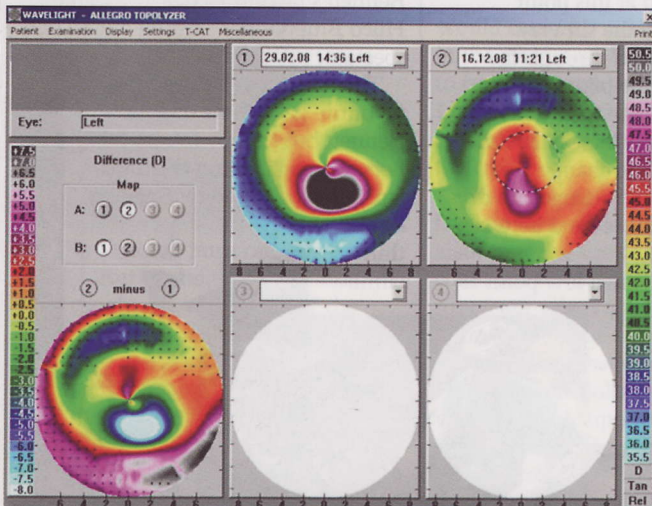


Figure 4 Postoperative result



(a) Topolyzer

(b) Oculus Pentacam

● Epithelial removal with Wavelight Allegretto laser (Figure 3).

T-CAT stromal ablation; topography-guided ablation profile: this includes ablation on the apex of the cone to flatten it, but also ablation on the opposite side of the optic zone to create relative steepening, in order to reduce the optic zone asymmetry.

- Twenty minutes' riboflavin application
- Thirty minutes' UV light exposure and riboflavin application
- Bandage contact lens.

Postoperative findings:  
10/12 Post-op T-CAT and cross-linking

- UCVA 6/7.5  
Rx plano/-1.50 x 100°  
BCVA 6/6
- Clear cornea
- One line gain BCVA
- Stabilised topography (Figure 4)
- Improved corneal symmetry. Reduced irregular astigmatism
- Note how the difference map (left

**Figure 5**  
**Results**  
**showing the**  
**difference**  
**in readings**

hand image on Topolyzer map display, Figure 5a) closely resembles the applied treatment profile

● Oculus Pentacam maps (Figures 4 and 5b) show improved corneal profile, and reduction of keratoconus indices (red boxes below maps).

## Management after T-CAT and cross-linking treatment

It would generally be two to three months before contact lens wear could be resumed following cross-linking or combined T-CAT and cross-linking. After either procedure, tolerance of RGP lenses may be improved, as there is some temporary diminution of corneal sensitivity. After T-CAT, the asymmetry may be sufficiently corrected to allow soft lens wear rather than RGP, and this may well be an indication for such treatment.

For those who do not wish to be reliant on spectacles or contact lenses, there is the option for phakic lens implantation once the refraction has been stabilised by the cross-linking. A gap of six to

12 months before embarking on such surgery should give assurance that the condition has indeed been arrested, but long-term follow-up will still be required.

## Conclusion

Management of keratoconus is often a significant challenge to both patient and practitioner. T-CAT and cross-linking offers a new tool in an expanding range of options now available, and may prove to be a valuable adjunct to more conventional therapies. ●

## Further information

Accuvision will be running further seminars on the treatment of keratoconus in September. If you are interested in attending, please send an email to john.andrews@accuvision.co.uk or call the clinic on 0845 000 2020.

● **Chad K Rostron** is a consultant ophthalmologist at Moorfields Eye Hospital and medical director at Accuvision Laser Eye Clinics London, Birmingham and Leeds